L'epilessia e le più comuni alterazioni encefaliche in età avanzata

associazione
italiana
veterinari
patologia
felina

aivpafe

Napoli, 4 Febbraio 2017

Cristian Falzone, dipl ECVN
Diagnostica Piccoli Animali
Zugliano (VI)
crisfalz@libero.it

Collaboratore c/o:
Centro Veterinario Caleidos, Albissola (SV)
Clinica Veterinaria Apuana, Massa (MS)

Epilessia

- Ripetersi nel tempo di crisi convulsive (>24h)
- Crisi Convu

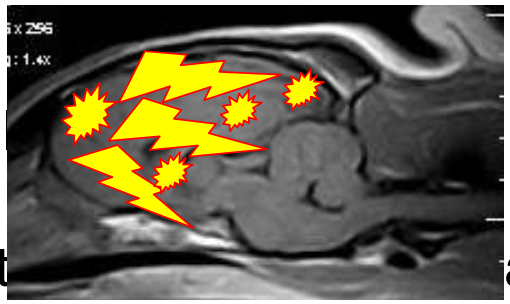

Event ari ad
att ed

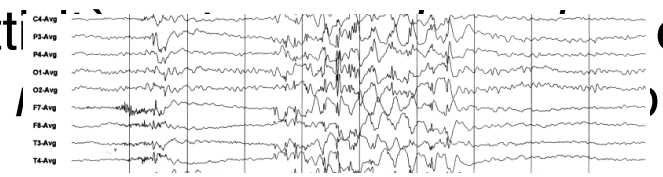

Epilessia

- Ripetersi nel tempo di crisi convulsive (>24h)
- Crisi Convulsive



Epilessia

- Ripetersi nel tempo di crisi convulsive (>24h)
- Epilessia primaria-idiopatica-congenita
- [

J Feline Med Surg. 2010 Dec;12(12):910-6. doi: 10.1016/j.jfms.2010.07.001. Epub 2010 Sep 6.

Clinical comparison of primary versus secondary epilepsy in 125 cats.

Pákozdy A[1], Leschnik M, Sarchahi AA, Tichy AG, Thalhammer JG.

Author information

Abstract

In the present study 125 cats with recurrent seizures were analysed. The main goal was to investigate the aetiology and compare primary epilepsy (PE) with secondary epilepsy (SE) regarding signalment, history, ictal pattern, clinical and neurological findings. Seizure aetiology was classified as PE in 47 (38%) and SE in 78 (62%) cats. SE was caused mainly by intracranial neoplasia (16), hippocampal necrosis (14), toxicosis (eight), and encephalitis (seven). A significant difference between PE and SE was found in: age, body weight, duration of seizure, occurrence of status epilepticus and neurological deficits. Status epilepticus, altered interictal neurological status and seizure onset over the age of 7 years indicated SE more frequently than PE. If the seizures occurred during resting conditions and rapid running occurred the aetiology was more likely to be PE than SE.

patologia organica extracranica (Eziologia)

Epilessia

- DIAGNOSI?
  - Patologia Intracranica
    - Patologia Metabolica
      - Forma Idiopatica

50% Gatti
70% Cani

Epilessia

- P

-In

-G

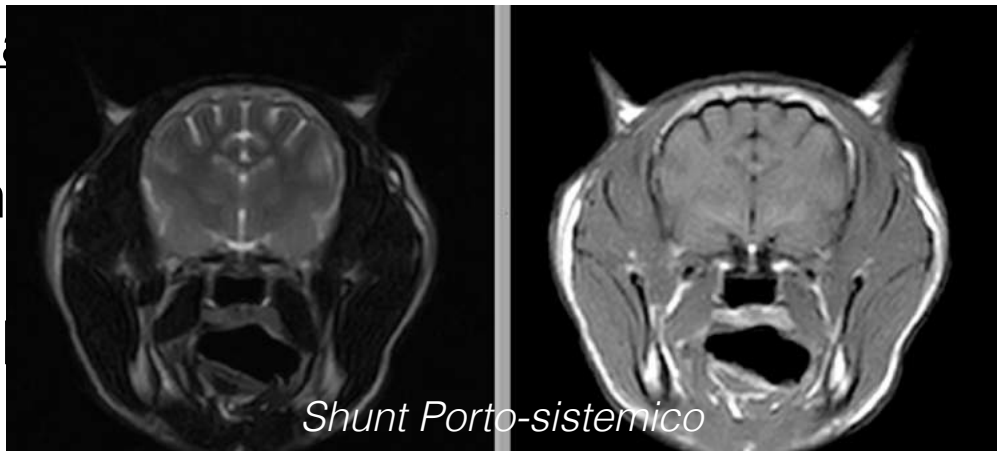

-Esami Ematobiochimici, urina

Epilessia

- Patologia Intracranica

-**Svogliati, letargici, disorientati**

-Disturbi della vista

-Atteggiamenti compulsivi

Epilessia

- Patologia Intracranica, Esame Neurologico

-Depressione del sensorio



Epilessia

- P[illegible]ca, [illegible]co

-D[illegible]ens[illegible]

-Al[illegible]ostural[illegible]

Epilessia

- Patologia Intracranica, Esame Neurologico

-Depression[illegible]

-Alterate rea[illegible]

-Alterata reazione di minaccia

Patologia Intracranica

VITAMIN D

Vascolari
Infiammatorie/infettive
Traumatiche
Anomalie
Metaboliche
Idiopatiche
Neoplastiche
Degenerative

Patologia Intracranica

VITAMIN D

Vascolari +
Infiammatorie/infettive +/-
Traumatiche -
Anomalie - -
Metaboliche
Idiopatiche
Neoplastiche ++
Degenerative -/+

NEOPLASIE

Pri

A p

Sec

Metas

Da str

J Vet Intern Med 2003;17:850–859

Feline Intracranial Neoplasia: Retrospective Review of 160 Cases (1985–2001)

Mark T. Troxel, Charles H. Vite, Thomas J. Van Winkle, Alisa L. Newton, Deena Tiches, Betsy Dayrell-Hart, Amy S. Kapatkin, Frances S. Shofer, and Sheldon A. Steinberg

The purpose of this study was to determine the frequency of different tumor types within a large cohort of cats with intracranial neoplasia and to attempt to correlate signalment, tumor size and location, and survival time for each tumor. Medical records of 160 cats with confirmed intracranial neoplasia evaluated between 1985 and 2001 were reviewed. Parameters evaluated included age, sex, breed, FeLV/FIV status, clinical signs, duration of signs, number of tumors, tumor location(s), imaging results, treatment, survival times, and histopathologic diagnosis. Most of the cats were older (11.3 ± 3.8 years). Primary tumors accounted for 70.6% of cases. Metastasis and direct extension of secondary tumors accounted for only 5.6 and 3.8% of cases, respectively. Twelve cats (7.5%) had 2 or more discrete tumors of the same type, whereas 16 cats (10.0%) had 2 different types of intracranial tumors. The most common tumor types were meningioma (n = 93, 58.1%), lymphoma (n = 23, 14.4%), pituitary tumors (n = 14, 8.8%), and gliomas (n = 12, 7.5%). The most common neurological signs were altered consciousness (n = 42, 26.2%), circling (n = 36, 22.5%), and seizures (n = 36, 22.5%). Cats without specific neurological signs were common (n = 34, 21.2%). The tumor was considered an incidental finding in 30 (18.8%) cats. In addition to expected relationships (eg, meninges and meningioma, pituitary and pituitary tumors), we found that lesion location was predictive of tumor type with diffuse cerebral or brainstem involvement predictive of lymphoma and third ventricle involvement predictive of meningioma.

Key words: Brain tumor; Cat; Diagnosis; Glioma; Lymphoma; Meningioma.

70.6% NPL Primitive

29,4% NPL Secondarie

NEOPLASIE

Incidenza

Cane, 1 - 3% di tutti i tumori, con una prevalenza di 14,4 su 100.000

Nel gatto la prevalenza è calcolata attorno a 3,5 casi su 100.000

NEOPLASIE

Segnalamento

Soggetti adulti-anziani

Insorgenza dei sintomi subdola e decorso sub-acuto cronico

NEOPLASIE

Segnalamento

Eccezioni

Soggetti Giovani
e insorgenza acuta/iperacuta

NEOPLASIE

Sospetto Clinico

Esami di Laboratorio, radiografie torace e ecografia addominale

IMAGING Encefalico

IMAGING ENCEFALICO

Ecografia: spt animali giovani

TC , buona per i mer a esecuzione

R in parenchima encefa dello spa

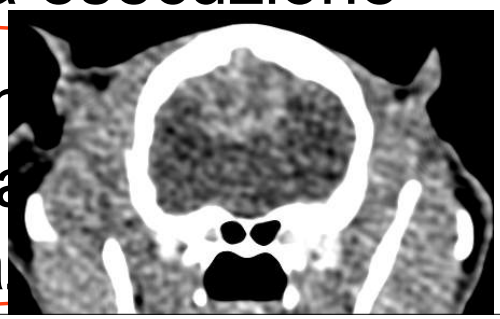

RMI

Sensibilità circa del 99%

Accuratezza ⩾ 70%

RMI

Alto campo

Basso campo

PROTOCOLLI RMI

3 Piani dello spazio

FSE T2-WI & SE T1-WI

FLAIR

SE T1 & FLAIR dopo Gadolinio

GE T2*, STIR

NEOPLASIE

Caratteristiche Morfologiche

numero, sede, forma, dimensioni, margini, rapporti strutture adiacenti

Caratteristiche di Segnale

Iso - Ipo - Iper Intenso, captazione di contrasto

NEOPLASIE

Alterazioni Secondarie

Edema perilesionale, ventricolomegalia, ernia cerebrale

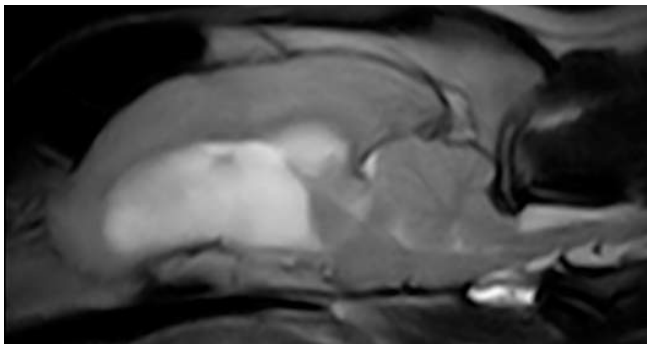

NEOPLASIE

Intra-assiale

Extra-assiale

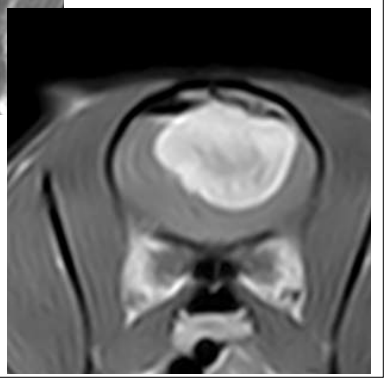

NEOPLASIE
MENINGIOMI

J Vet Intern Med 2003;17:850–859

Feline Intracranial Neoplasia: Retrospective Review of 160 Cases (1985–2001)

Mark T. Troxel, Charles H. Vite, Thomas J. Van Winkle, Alisa L. Newton, Deena Tiches, Betsy Dayrell-Hart, Amy S. Kapatkin, Frances S. Shofer, and Sheldon A. Steinberg

Tum

Origi

Si svil

Cerel

Meningiomi	58.4%
Linfomi	14.4%
Tumori pituitari	8.8%
Gliomi	7.5%
Altro	11.2%

NEOPLASIE
MENINGIOMI

Età media 10-13 anni circa

Maschi: Femina: 2-3:1

22% (50%) rilevati incidentalmente post-mortem

NEOPLASIE
MENINGIOMI

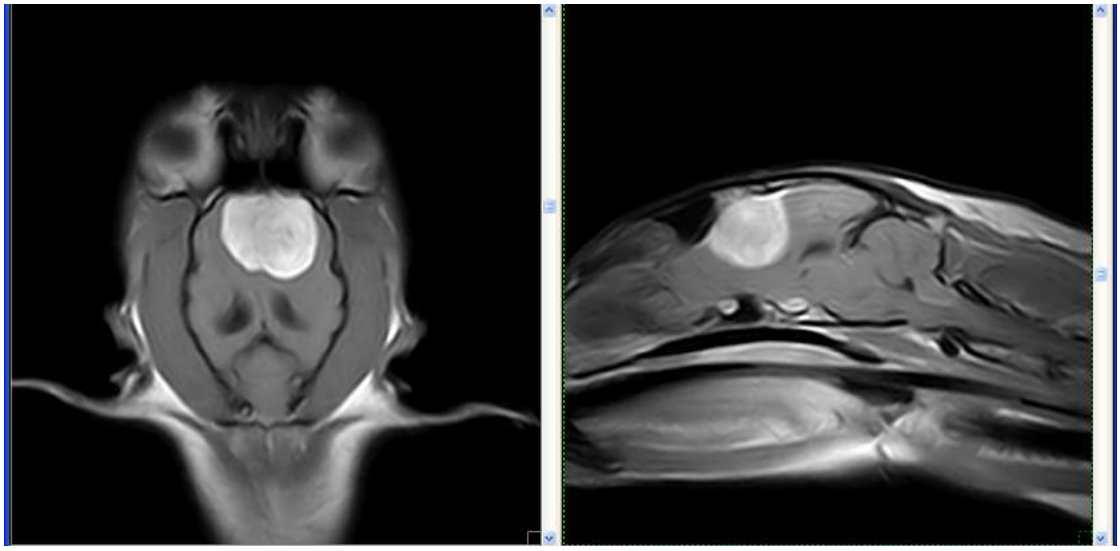

NEOPLASIE
MENINGIOMI

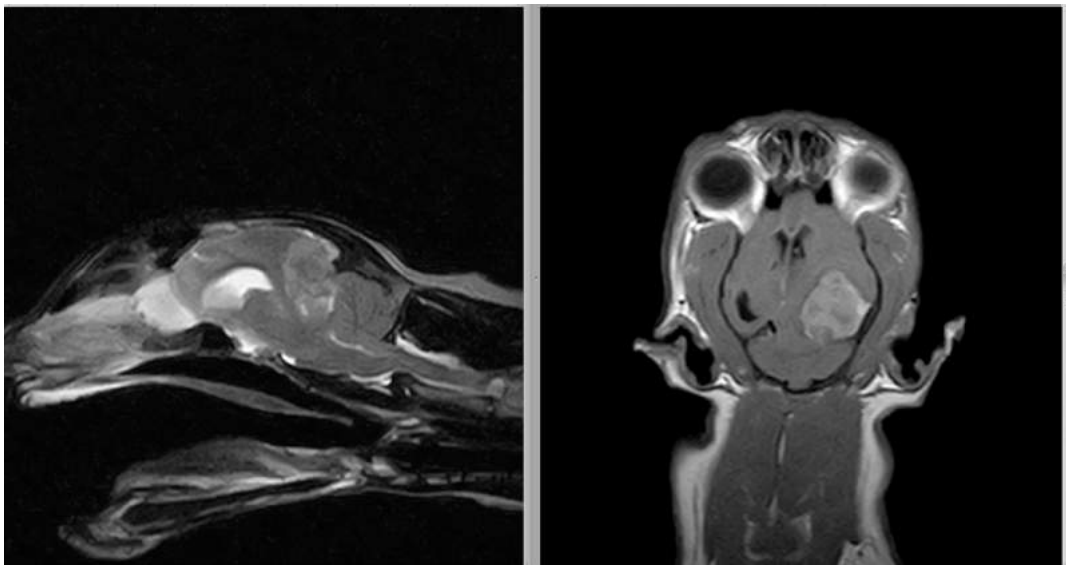

NEOPLASIE
MENINGIOMI

PICCOLI MA RILEVANTI!

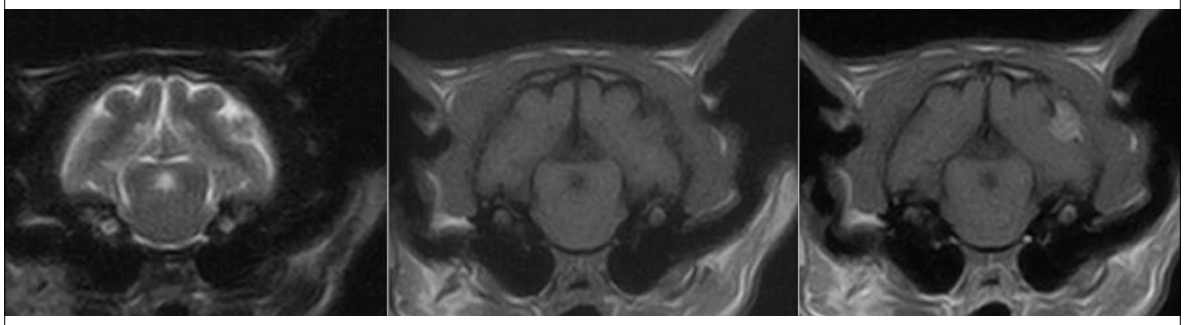

IMPORTANZA DEL MEZZO DI CONTRASTO!

NEOPLASIE
MENINGIOMI

NEOPLASIE
MENINGIOMI

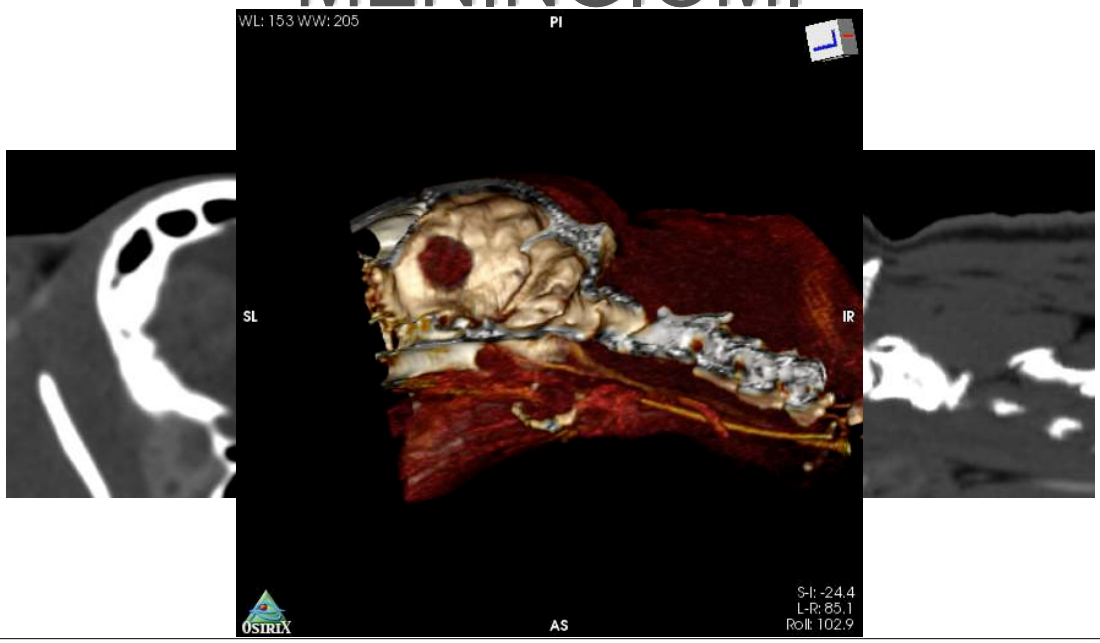

NEOPLASIE
LINFOMA

Sec

Prir

Sing

Età

Grande trasformista!

MRI FEATURES OF CNS LYMPHOMA IN DOGS AND CATS

VIKTOR PALUS, HOLGER A. VOLK, CHRISTOPHER R. LAMB, MIKE P. TARGETT, GIUNIO BRUTO CHERUBINI

The magnetic resonance (MR) imaging features of central nervous system lymphoma in eight dogs and four cats are described. Intracranial lesions affected the rostrotentorial structures in six dogs and caudotentorial structures in two cats. Lesions affected the spinal cord in two dogs and in two cats. One dog and one cat with intracranial lymphoma had signs of local extracranial extension and lymphadenopathy. Lesions were considered extraparenchymal in four dogs and three cats, intraparenchymal in two dogs and one cat, and appeared to have both intra- and extraparenchymal components in two dogs. All lesions were hyperintense in T2-weighted images when compared to white matter, most were hypointense in T1-weighted images (7/12), and most were hyperintense in fluid-attenuated inversion recovery (FLAIR) images (5/9). When compared to grey matter, these lesions appear either isointense (5/12) or hyperintense (7/12) on T2-weighted images, half of them were hypointense in T1-weighted images (6/12), and most were isointense in FLAIR images (7/9). Lesion margins were usually indistinct in T2-weighted images (10/12) and had perilesional hyperintensity in FLAIR images (7/9). The majority of lesions (10/12) had abnormal meninges around the lesion and half (6/12) had generalized contrast enhancement. Mass effect was evident in all lesions. Although not specific, when combined with the history and neurologic signs, MR features aid presumptive diagnosis that should be confirmed by cytology or histopathology. © 2012 *Veterinary Radiology & Ultrasound, Vol. 53, No. 1, 2012, pp 44–49.*

NEOPLASIE
LINFOMA

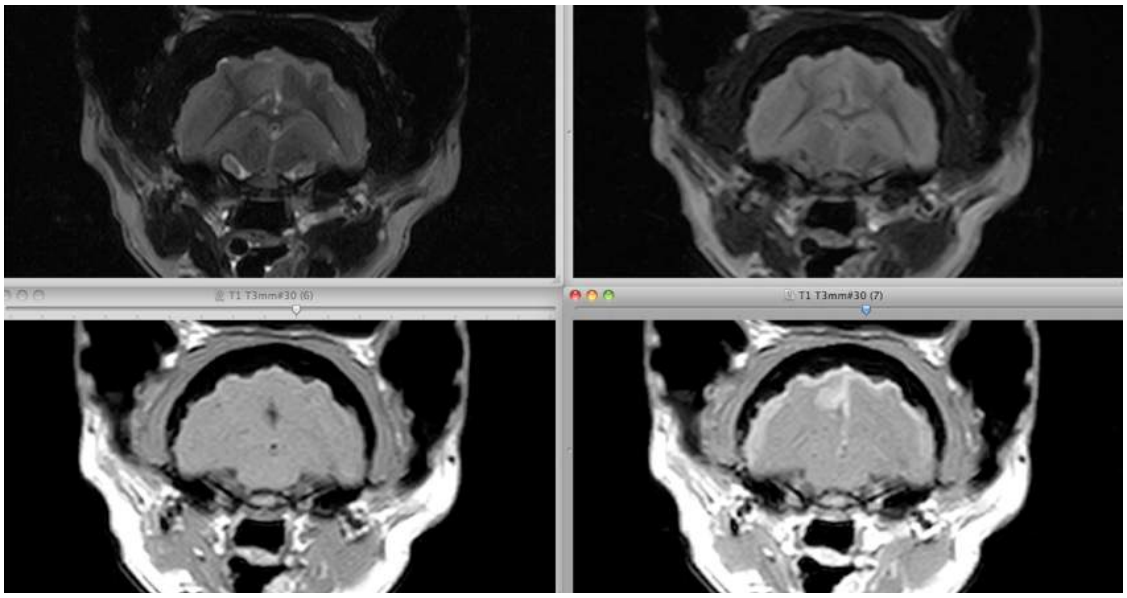

NEOPLASIE
LINFOMA

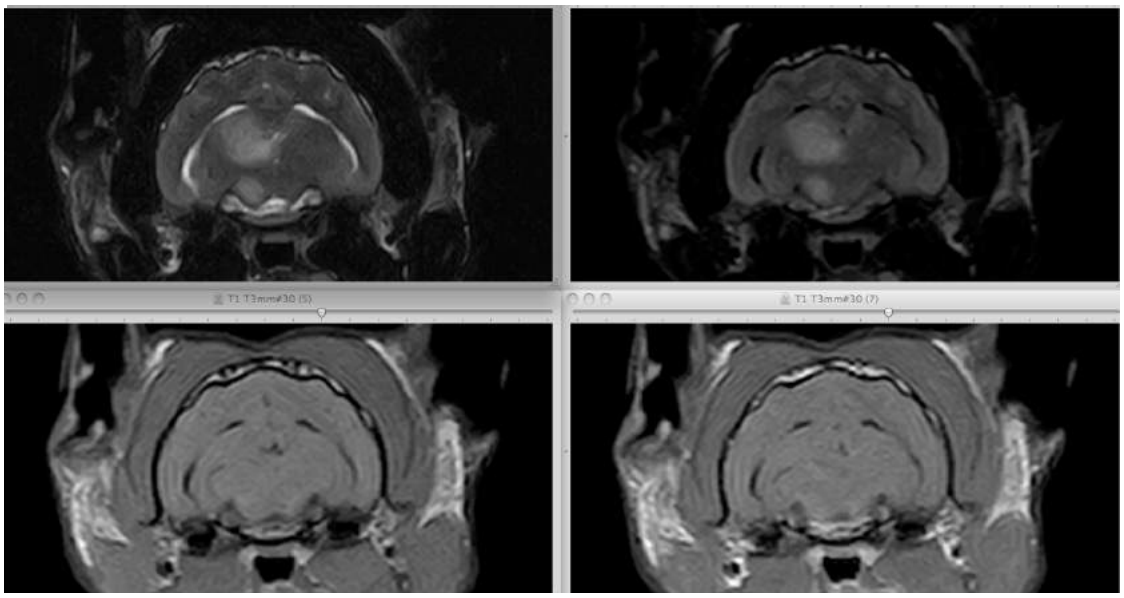

NEOPLASIE

LINFOMA

LIQUIDO CEFALORACHIDIANO

Quas CHE!!!!

Aume proteico

Pleoc nocitica

Disso

RARI i linfoblasti o caratteri di atipia cellulare

J Vet Intern Med 2003;17:850–859

Feline Intracranial Neoplasia: Retrospective Review of 160 Cases (1985–2001)

Mark T. Troxel, Charles H. Vite, Thomas J. Van Winkle, Alisa L. Newton, Deena Tiches, Betsy Dayrell-Hart, Amy S. Kapatkin, Frances S. Shofer, and Sheldon A. Steinberg

The purpose of this study was to determine the frequency of different tumor types within a large cohort of cats with intracranial neoplasia and to attempt to correlate signalment, tumor size and location, and survival time for each tumor. Medical records of 160 cats with included age, sex, breed atment, survival times r 70.6% of cases. Mets lve cats (7.5%) had 2 ors. The most common %), and gliomas (n = n = 36, 22.5%), and s nor was considered an pituitary and pituitary tumors), we found that lesion location was predictive of tumor type with diffuse cerebral or brainstem involvement predictive of lymphoma and third ventricle involvement predictive of meningioma.

Key words: Brain tumor; Cat; Diagnosis; Glioma; Lymphoma; Meningioma.

Linfoblasti in 1 gatto
17% FeLV +

NEOPLASIE

ALTRO

NEOPLASIE
ADENOMA IPOFISARIO

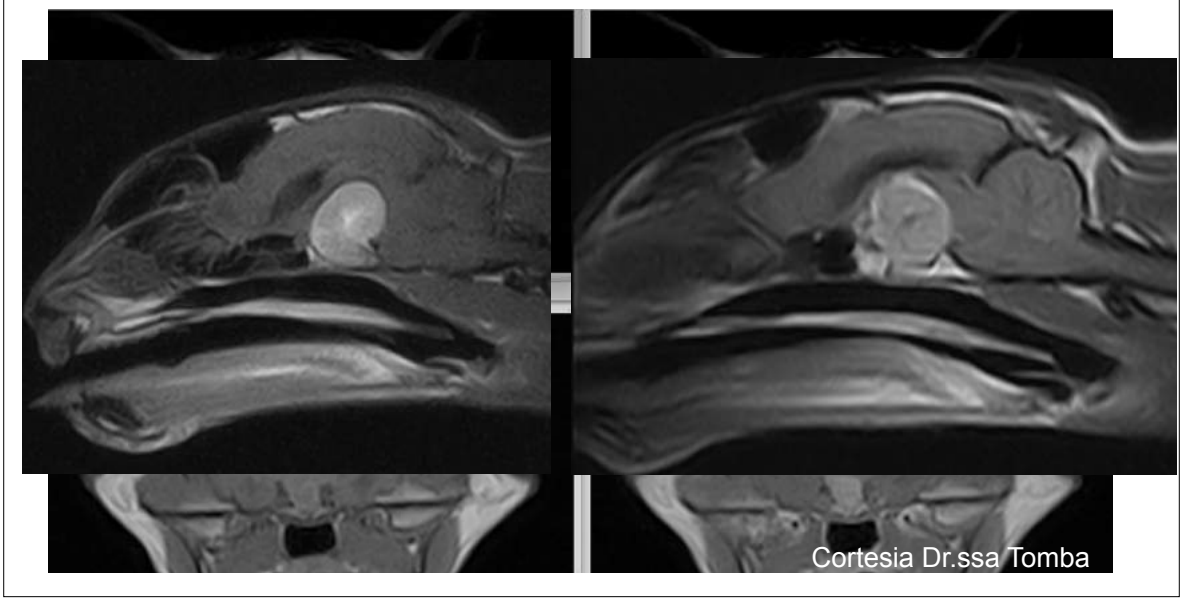

NEOPLASIE
TUMORE DEI PLESSI CORIODEI O MENINGIOMA?!

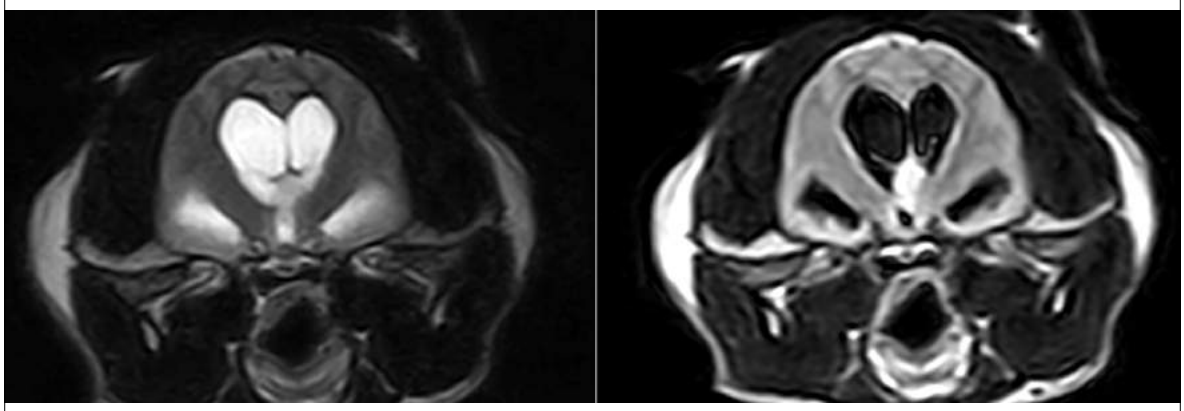

NEOPLASIE

GLIOMA???

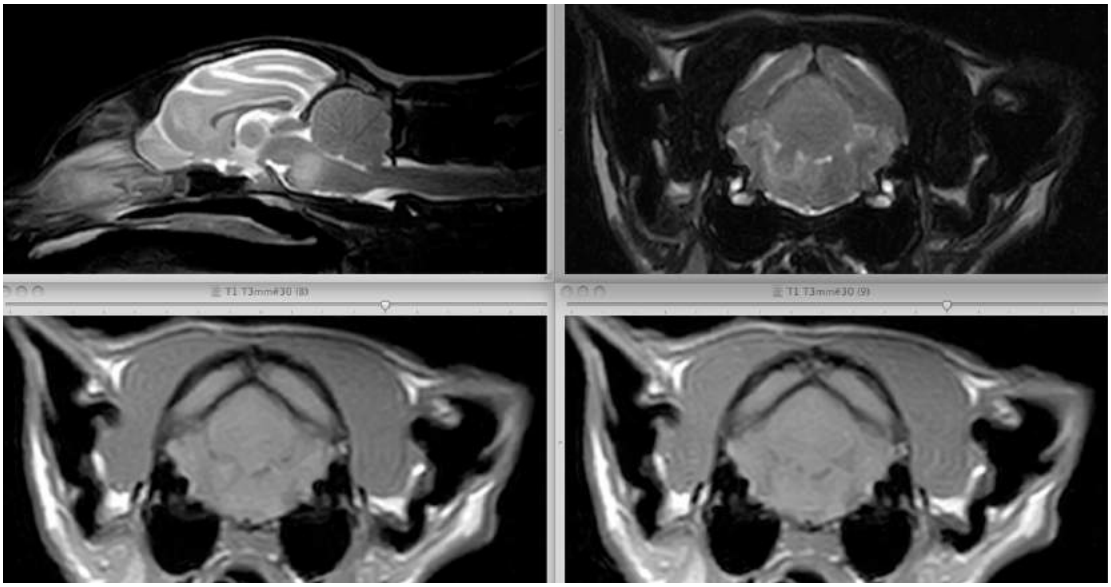

RMI

Sensibilità circa del 99%

Accuratezza > 70%

Esame istologico!

NEOPLASIE

??????????

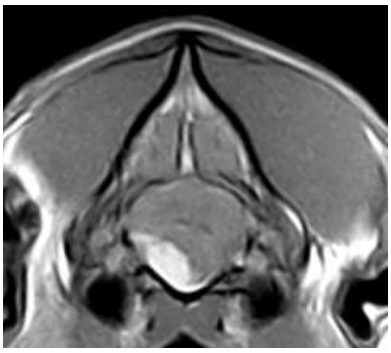

Meningioma

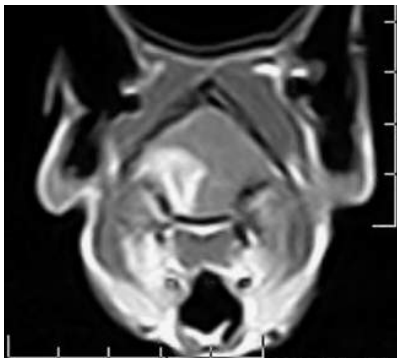

ME Otogenica

NEOPLASIE

??????????

Meningioma

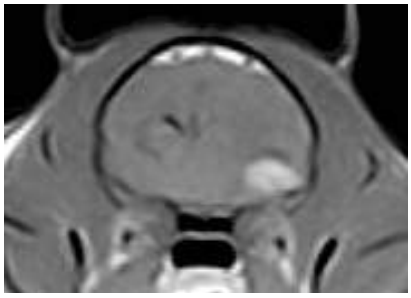

T.gondii ME

VASCOLARI

“ACCIDENTI” CEREBRO-VASCOLARI

ISCHEMICI

EM

Ipertensione, Insufficienza renale,
Cardiomiopatia ipertrofica

VASCOLARI

ACCIDENTI CEREBRO-VASCOLARI

Ischemici

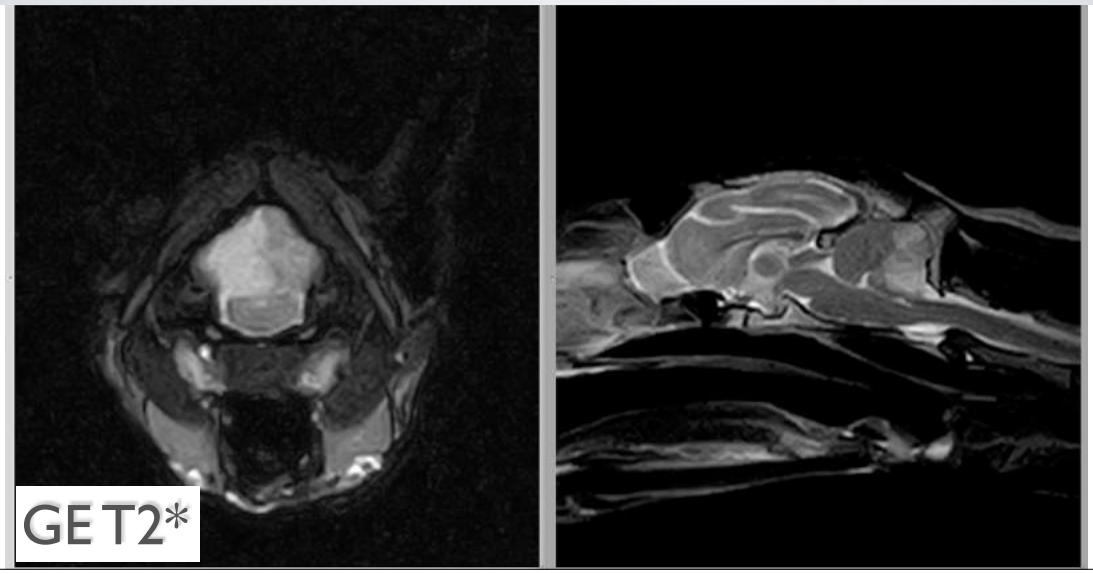

VASCOLARI

ACCIDENTI CEREBRO-VASCOLARI

Ischemici

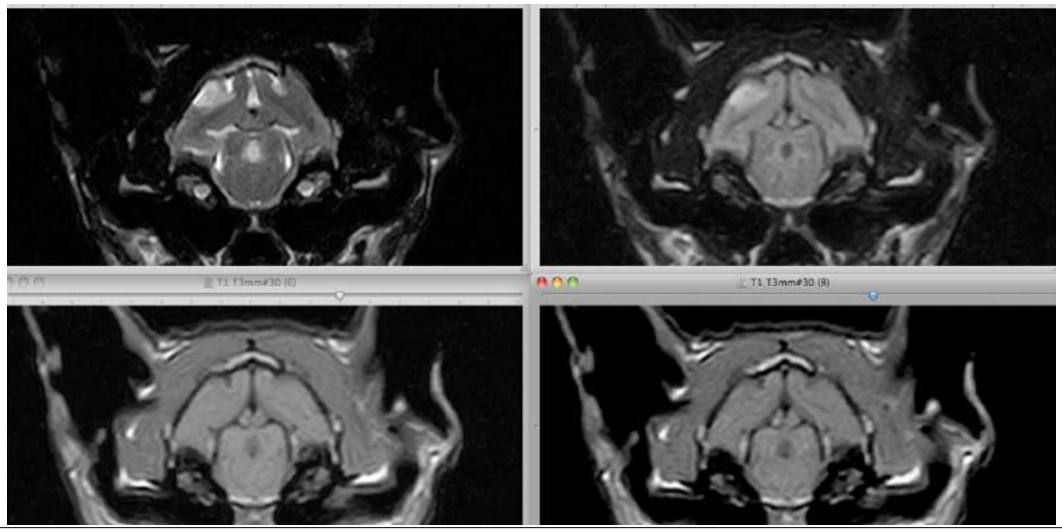

VASCOLARI

ACCIDENTI CEREBRO-VASCOLARI

Ischemici

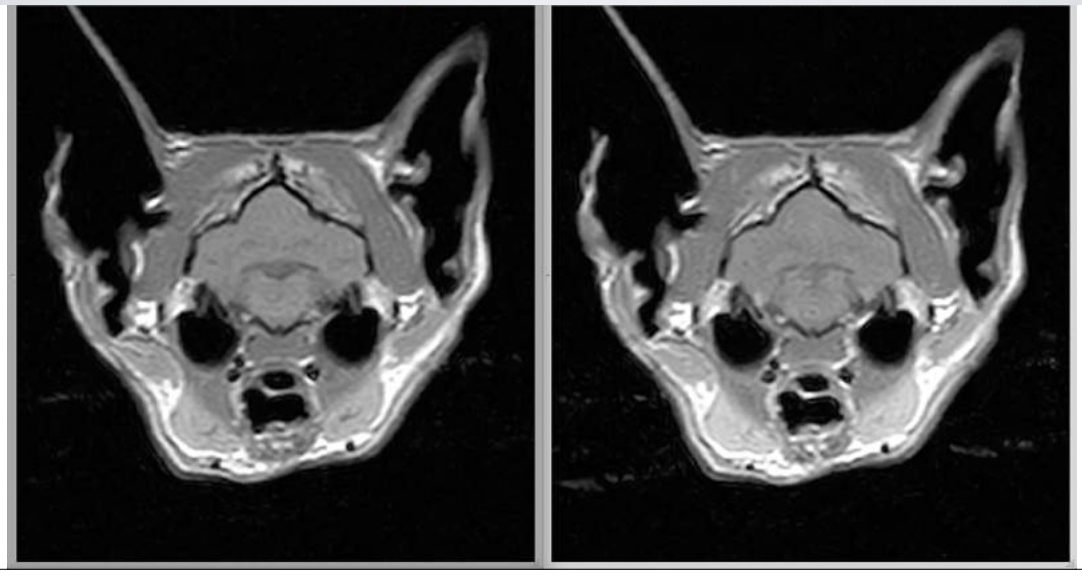

VASCOLARI

ACCIDENTI CEREBRO-VASCOLARI

Emorragici

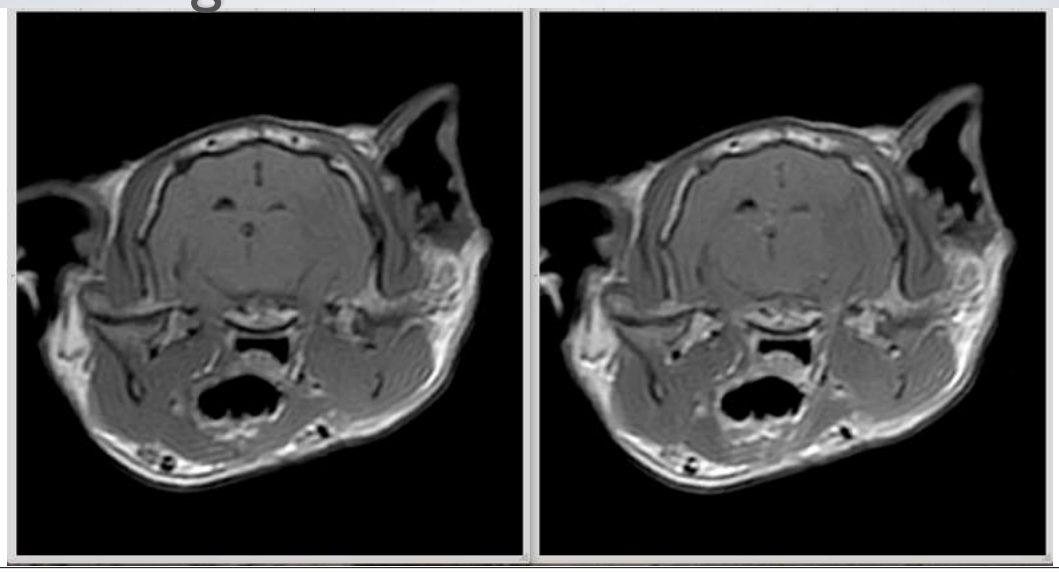

VASCOLARI

ACCIDENTI CEREBRO-VASCOLARI

Emorragici

Primari,

Rari

Secondari,

Malformazioni, **Neoplasie**, Traumi, Parassiti, etc.